

**► HYDROTHERAPY**

## Time for a Swim

### THE BENEFITS OF NEONATAL HYDROTHERAPY

By Karen Goldberg, MS, PT, PCS

**N**eonatal hydrotherapy was conceptualized in 1980 at the Madigan Army Medical Center in Tacoma, Washington.<sup>9</sup> It is a modality of pediatric physical therapy treatment that integrates therapeutic exercises, neuromuscular reeducation, and functional training.

At Danbury Hospital in Danbury, Connecticut, neonatal hydrotherapy is provided to promote neonatal movement for those infants who demonstrate a paucity of spontaneous generalized movements and who also demonstrate poor primary movement repertoires, such as reciprocal leg kicking and hand to mouth. These findings have been correlated with abnormal development.<sup>6</sup>

It has also been found that this treatment often promotes improved state control and state regulation, especially for infants diagnosed with neonatal abstinence syndrome.<sup>12</sup> Neonatal abstinence syndrome consists of a wide variety of central nervous system signs of irritability, (jitteriness, increased tone), gastrointestinal problems (hyperphagia, diarrhea), respiratory symptoms (tachypnea) and autonomic dysfunction.<sup>12</sup>

Sweeney has reported that there is improved feeding proficiency in preterm neonates following hydrotherapy in the NICU setting.<sup>10</sup> Feeding proficiency was measured by duration of feeding which was decreased and (continued on page 8)

## Pediatric Orthopedics Part IIIa:

### SAGITTAL PLANE ISSUES AND ACHIEVEMENTS

By Beverly Cusick, PT, MS, COF/BOC

**I**n Part I of this series [Network, March/April 2006], we reviewed the influences of normal, strain-inducing, mechanical loads on developing bone geometry and joints. In Part II [Network, July/August 2006], we examined the connective and muscle tissues in similar contexts, with a discussion of the relationship between the history of muscle recruitment and clinical evidence of muscle imbalances and soft tissue transformation. Suffice to say that our understanding of the transformation process is still evolving.

In the final three installments, I'll discuss musculoskeletal changes in the spine and lower extremities as they emerge in each cardinal plane, beginning in the sagittal plane in this piece, and progressing into the frontal and transverse planes.<sup>1</sup>

Self-organized movement skills develop in the

presence of a system of body segments that are normally linked by soft tissue constraints (Table 1). The intrauterine, flexed-limb position is the most common prenatal position. Full-term healthy neonates, therefore, typically exhibit "physiologic flexion," a remarkably strong, active-and-passive resistance to passive limb joint extension.<sup>1</sup> The shortened state of the muscles, connective tissues, blood vessels, nerves, and skin—all located on the concave side of the flexed joints—follows the final two months of marked body-size increase in utero. By limiting the degrees of freedom in developing movements, the neonatal soft-tissue constraints mechanically guide the course of musculoskeletal as well as neuromotor development.<sup>2,3</sup> (continued on page 10)

**TABLE 1**

TORSO	HIP JOINTS	KNEE JOINTS	ANKLE JOINTS
<b>Muscles:</b> Pectorals Rectus Abdominus Oblique Abdominals Transverse Abdominus	<b>Muscles:</b> Iliopsoas Proximal Rectus Femoris Piriformis Superior & inferior gemellae	<b>Muscles:</b> All distal hamstrings Distal Gracilis Distal Sartorius Popliteus	<b>Muscles:</b> Tibialis Anterior Extensor Digitorum Longus
<b>Ligaments:</b> Anterior intervertebrals Anterior aponeurosis Inguinal	<b>Ligaments:</b> Iliofemoral Anterior capsule	<b>Ligaments:</b> Posterior/medial capsule Anterior cruciate Posterior medial collateral	<b>Ligaments:</b> Anterior joint capsule Anterior talofibular Anterior deltoid fibers
<b>Associated nerves, blood vessels, and skin</b>	<b>Associated nerves, blood vessels, and skin</b>	<b>Associated nerves, blood vessels, and skin</b>	<b>Associated nerves, blood vessels, and skin</b>

**INSIDE THE NETWORK :**
**3** President's Message | **4** Upcoming Conference | **5** Clinician's Corner: Tummy Time

**7** Patient Perspective: Find a Therapist | **19** Therapy Talk: Orthotics

(Pediatric Orthopedics Part IIIa continued from page 1)

## SAGITTAL-PLANE DEVELOPMENTAL CHANGES

Sagittal-plane extension against gravity is the first component of volitional control to emerge, in a cephalocaudal and proximal-to-distal progression. Antigravity flexion soon follows. Sagittal-plane antigravity skills appear to operate as the foundation for the development of postural control and movement.<sup>1,3</sup> I refer the reader to Lois Bly's publications for detailed and illustrated presentations of the infant's acquisition of motor skills, and have narrowed my focus to the underlying orthopedics.

### The Spine and Pelvis – Orthopedic Features

The secondary curvature in the cervical spine of the human fetus develops soon after the embryo first acquires a neck and begins to uncurl. The early appearance of this curvature may be related to the early development of function in the muscles responsible for head extension.<sup>4</sup> The neonatal thoracolumbar spine is kyphotic, and the pelvis aligns in a posterior tilt (Fig.1).<sup>5,6</sup> The ribs align perpendicular to the spine, rendering the thoracic spine relatively immobile. The pelvis is somewhat circular in the transverse plane, as the proximal sacrum is narrow and the iliac plates have yet to broaden.

### The Skeletal Modeling Objective:

The neonatal thoracolumbar kyphosis must be converted to the three-curved design of maturity. The vertebrae grow rapidly between birth and age two years, with 50% of the total growth of the spine occurring by age 12 months. The lumbar intervertebral disks accommodate the developing lordosis by developing a wedge-shaped configuration.<sup>7</sup>

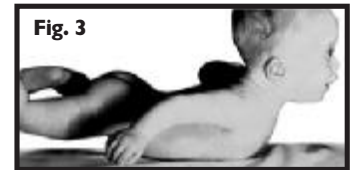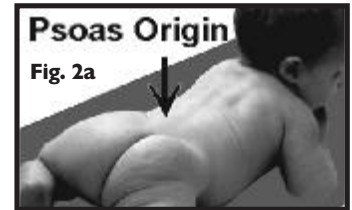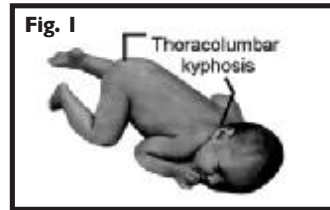
### Available Tools and Mechanisms:

Skeletal plasticity (water-loaded cartilage), modeling mechanisms (strains and sensors, a.k.a. mechanostats), gravity, emerging anti-gravity trunk extensor muscle function, and soft tissue constraints.

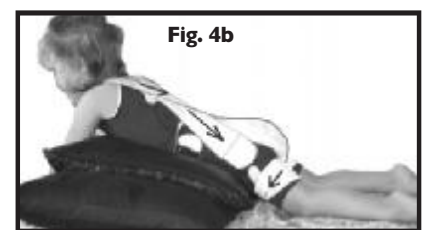
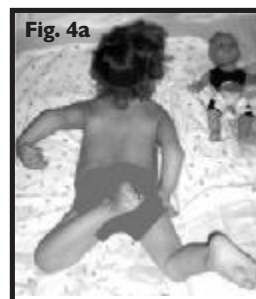
### The Contributing Role of Soft-Tissue Constraints:

In early infancy, while the cervical and lumbar spines gain lordotic curves, the abdominal aponeurosis connecting the sternum, iliac crests, and ischium pubis, and the barrel-shaped ribcage combine to limit thoracic extension, preserving the kyphotic curve. The newborn hip flexion contracture averages 30° and is a sturdy mechanical constraint imposed by the shortened iliofemoral ligament and anterior hip capsule, and the proximal rectus femoris (RF) and iliopsoas (IP) muscles. The RF originates on the anterior pelvis, at the anterior inferior iliac spines, and the psoas originates on the anterior lumbar vertebrae. The limitation on hip joint extension ROM channels the emerging trunk extension effort occurring in prone position to the lumbar spine (Fig.2a).

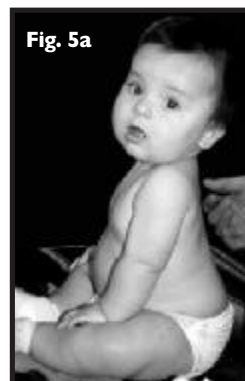The infant uses relative flexibility (*my hips don't extend, so what will?*) to correct neonatal lumbar kyphosis *long before* reducing the hip flexion contracture. The infant who lacks a competent hip flexion constraint might benefit from early intervention with a TheraTogs system that mimics the influence of the IP constraint—bringing the hips into flexion (continued on page 11)




**Fig. 1.** Neonatal kyphosis, posterior pelvic tilt. Hip flexion contracture keeps the pelvis elevated, which facilitates random kicking. **Fig. 2a.** By age four months, the residual hip flexion contracture drives the lumbar spine into extension and the pelvis into anterior tilt. **Fig. 2b.** TheraTogs IP strapping promotes hip flexion, lateral rotation, and lumbar extension supports this spine-shaping effect. **Fig. 3.** Age five to six months. "Landau swimming" shortens and strengthens trunk extensors, scapular adductors and depressors, and elongates Rectus Abdominus and pectorals.



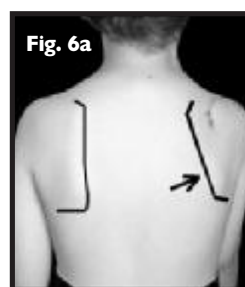
**Fig. 4a.** Age five years, athetoid/dystonic quadriplegia. Disorganized antigravity extension, with left hip lateral rotation and abduction. **Fig. 4b.** Kylie, prone on wedged pillows with TheraTogs crossed stretch straps for trunk extension and hip abduction assist, and thigh wrap to reduce lateral rotation and abduction.



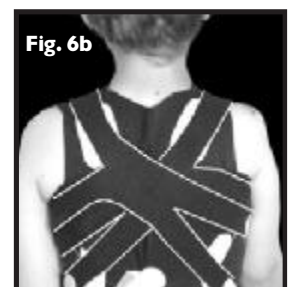**Fig. 5a.** Age six months, developmental delay with hypotonia. Immature sitting — lumbar flexion, shoulder retraction.



**Fig. 5b.** Same session, wearing a split strap for lumbar and hip extension assist.



**Fig. 6a.** Age nine years, scapular instability and excessive abduction.



**Fig. 6b.** TheraTogs split straps to shorten and assist middle and lower trapezius and right rhomboids muscles.

(*Pediatric Orthopedics Part IIIa continued from page 10*)

and lateral rotation with a connecting lumbar extension strap (Fig. 2b).

The newborn spinal and hip extensors and scapular adductors and depressors are in lengthened state (Fig 1). Ideally, within six months, the infant successfully and actively shortens and strengthens these antigravity and stabilizing muscles (Fig.3). With this achievement, the infant has laid the foundation for the ensuing development of postural control and movement. TheraTogs applications designed to support this achievement are presented in Figs. 4-6a.

### POSTURE AND PELVIC TILT

At age four months, postural symmetry in prone and supine positions is a significant hallmark of appropriate musculoskeletal development.<sup>1</sup> By age six to seven months, the infant sits with a straight and vertical spine and sacrum, with the weight line on the inferior ischial tuberosities, implementing newly-gained strength and length reduction of the trunk and hip extensors—essential component number one—and abdominal control—essential component number two.

Around age 12 months, the standing infant exhibits a relatively flat lumbar spine, while the hips and knees align in flexion (Fig.7). The mechanical constraints of immature lumbar vertebral disk shape and limited lower spine extension ROM join the lack of hip extension ROM, and result in the prevailing attitude of slight lower extremity (LE) joint flexion that lowers the center of mass (COM),



Fig. 7

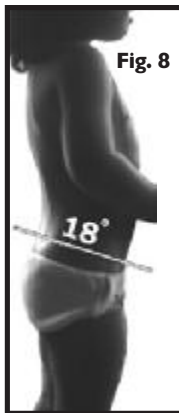

Fig. 8

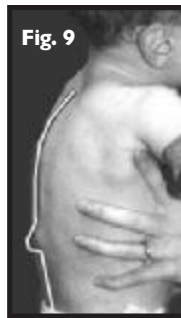

Fig. 9

**Fig. 7.** Age 12 months. Lowered COM with hip flexion is due to IP constraint – and accommodates it. **Fig. 8.** Age 30 months. Anterior pelvic tilt falls between 10° and 20°. **Fig. 9.** Age 32 months. Spastic CP. Excessive thoracolumbar kyphosis, reduced pelvic tilt.

improving upright stability. Lumbar lordosis and anterior pelvic tilt increase in magnitude through age two to four years, and gradually reduce again with improved abdominal and hip extension control over pelvic alignment. Two superior sacral processes align anterior to the transverse processes on the fifth lumbar vertebra, securing the latter against slipping anteriorly.

The brief period of increased anterior tilt might provide an added compression to the sacral facets, with a resulting increase in their

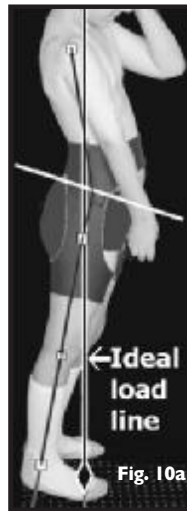

Fig. 10a



Fig. 10b

**Fig. 10a.** Age 9 years. OBPI with hypotonia. **Fig. 10b.** Scapular, abdominal, and hip abduction strapping.

growth rate. Normal anterior pelvic tilt at ages three to five years usually falls between 10° and 20° (Fig. 8). The adult norms for anterior pelvic tilt (8°-13° in males<sup>8,9</sup> and 10°-22° in females<sup>10</sup>) are evident at ages eight to 10 years.

### CLINICAL IMPLICATION OF SAGITTAL-PLANE POSTURAL DEVELOPMENT

*The fundamental achievement of neck and trunk extension against gravity is commonly compromised in children born with variable or abnormally high or low*

*tone (i.e. resistance to passive elongation), ligament laxity, generalized weakness, and dyspraxia. Children born before the final two months of gestation might lack the normal hip flexion constraints that promote lumbar curve formation.*

*Inadequate achievement of antigravity trunk extension can leave the spine kyphotic, the rectus abdominus short, and the shoulders protracted (Fig. 9). Pediatric therapists who engage in neuromotor re-education might consider fostering sagittal-plane righting and movement strategies (vs. frontal-plane activities like lateral tipping on a big ball) to build fundamental ingredients of strength in extension and flexion.*

*Pelvic tilt affects the alignment of the superior articular processes on the sacrum, such that they tilt forward with increased anterior pelvic tilt, compromising their stabilizing effect. Spondylolisthesis is a possible consequence. Since most norms are acquired in cross-sectional rather than longitudinal studies, they often fail to acknowledge long-term consequences of existing pathomechanics. Since the incidence of low back pain is high among adults, I prefer to strive to achieve the ideal anterior pelvic tilt of 10° by age eight years.<sup>10</sup>*

*For postural malalignment related to ligament laxity, hypotonia, and/or dyspraxia (Fig. 10a), strapping might be used to assist thoracic extensors, scapular adductors and depressors, lower abdominals, and perhaps the hip abductors (Fig. 10b), combined with an accompanying strengthening program.*

### JOINT RANGE OF MOTION (ROM): PUBLISHED DATA/CURRENT RECORDING PRACTICES

ROM test results were once recorded as single end range findings obtained by moving a part in one direction until an end range is detected. In recent years, clinicians have been instructed to record the full available ROM—using the anatomical position as 0°—for a selected plane of motion at the joint.<sup>11</sup> For example, a hip extension range limitation of 20°, once recorded as a minus (-) 20°, would now appear as a finding of “S (for sagittal plane): 0-20-135”, to show that the normal starting (anatomical) hip position is 0°, but in this case, it is flexed 20°, while full flexion to 135° is available at the ending position.

As the bulk of the literature on pediatric ROM norms was written before—or without using—this change in documentation, and generally presents single end-range findings, they are repre- (*continued on page 12*)



*(Pediatric Orthopedics Part IIIa continued from page 11)*

sented that way here, with descriptions of reported reference axes. When a joint angle of  $0^\circ$  is either the joint motion goal or the reference position, I indicate a lack of full motion with a (-) minus sign.

On the issue of reliability of reported musculoskeletal assessment findings, it is safe to say that many norms are poorly supported by precise assessment techniques, and that reliability studies that employ faulty techniques commonly show poor results. Studies of soft tissue extensibility have revealed that even the time of day must be standardized to reduce variability in findings.<sup>12,13</sup> I consider the existing body of information pertaining to normal lower extremity musculoskeletal development to be a work in progress, awaiting the use of considerably more rigorous assessment techniques, including harmless imaging. (After scrutinizing, using, and continually refining a battery of postural and lower-extremity assessments over 22 years, I've produced and updated the DVD: *Legs & Feet: A Review of Musculoskeletal Assessments*, 3rd ed. 2005, available at [www.gaitways.com](http://www.gaitways.com).)

## THE HIP JOINT

The neonate exhibits a hip extension ROM deficit averaging  $\sim 30^\circ$  from a lateral pelvic reference line drawn perpendicular to the tangent of the ASIS and PSIS (Fig. 11).<sup>14</sup> The IP is the primary shortened muscle, accompanied by the proximal portion of the RF muscle.

The neonatal hip extension deficit undergoes  $\sim 8$  years of developmental resolution, beginning with the early influences of gravity, handling, and normal neonatal random kicking. The mean extension deficit diminishes to  $19^\circ$  at age six weeks, and  $7^\circ$  at age six months.<sup>15</sup>

At age three-to-four months, the gluteal muscles are visibly active in prone position. By age five to six months, the anterior pelvis can usually lay flat on the floor when the infant is propping in prone position.

Movement activities, such as high climbing, strengthen the hip extensors in shortened position, and add length demands to the

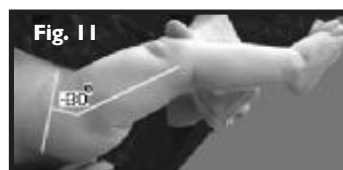

Fig. 11 Normal neonatal hip flexion contracture.



hip flexors (Fig. 12). Phelps et al (1985) used the Prone Hip Extension Test developed by Staheli<sup>16</sup> to obtain normative ROM data for children between ages 9 and 24 months, and found mean hip



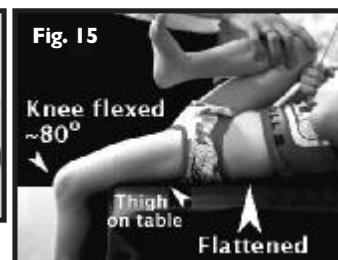Fig. 12. Age 10 months. Active hip extension with high climbing elongates IP.

Fig. 13. Age 2 years. Hip extension ROM deficit is still evident in gait.



Fig. 14. Age 7 years. Prone hip

extension test shows extension ROM  $>0^\circ$ . Fig. 15. Age 8 years. Ideal Two-Joint Hip Flexor ROM Test results, with thigh in sagittal plane and perpendicular to the pelvis.



extension ROM deficits of  $9^\circ$  at age 12 months (i.e.  $-9^\circ$ , with  $0^\circ$  occurring when the femur is parallel to the table), and  $3^\circ$  at age 24 months.<sup>17</sup> The prone hip extension test was not refined to standardize pelvic position on the table or pelvic reference axes at the time of Phelps's study, and has not been normed for children older than age two years. At age two years, residual hip flexion persists in standing and gait, and continues to drive an increase in lumbar hyperextension (Fig. 13).

In my experience—having modified the prone hip extension test of IP extensibility for improved replicability—nondisabled children age  $\geq 4$  years usually show  $R_1$  hip extension ROM of  $0^\circ$  ( $\pm 5^\circ$ ), and by age eight years, the same finding has increased to  $+5^\circ$  to  $+10^\circ$ , the range needed for optimum hip extension at terminal midstance in the gait cycle (Fig. 14). Adult hip extension ROM is normally  $\sim +10^\circ$ .<sup>18,19</sup>

## THE TWO-JOINT HIP FLEXOR ROM TEST

The RF is an energy transfer strap that assists swing-phase hip flexion and swing-phase knee extension, with resulting increased gait efficiency. It is an open-chain, two-joint muscle. By age eight years, a supine, two-joint, hip extension ROM test—executed with the lumbar spine in normal extension (not flat)—ideally results in full sagittal-plane hip extension, and knee flexion  $\geq \sim 80^\circ$  (Fig. 15).<sup>21,20</sup> Younger children show a similar test result that features a slightly elevated thigh. The sagittal plane hip alignment and flexed knee indicate that neither RF nor Tensor Fascia Lata (TFL) is dominant over the IP or the quadriceps.

(continued on page 13)

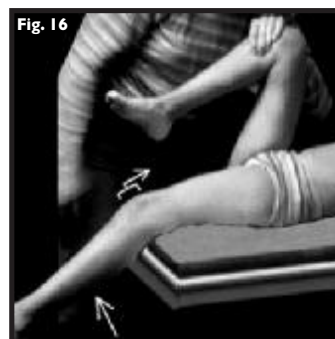

Fig. 16. Two-Joint Test—Positive for RF dominance.

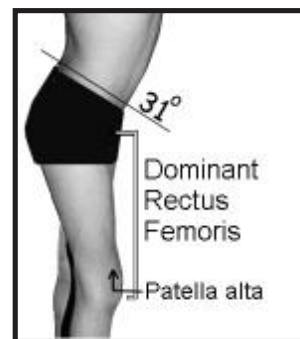


Fig. 17. Relative flexibility issues pertaining to dominant RF.

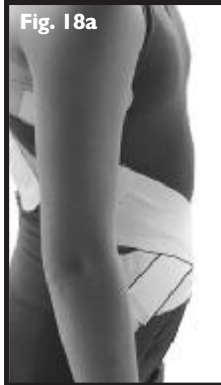

Fig. 18a

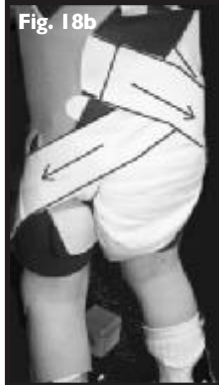
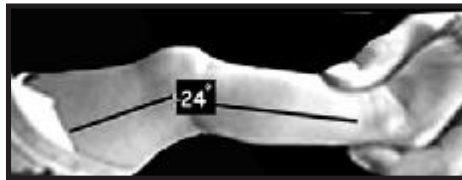
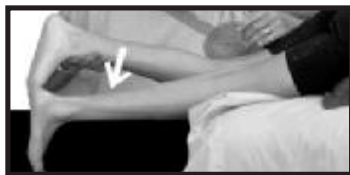Fig. 18b

**Fig. 18a.** Protecting a relative flexibility site—L5/S1—by strapping to shorten lower abdominals.

**Fig. 18b.** Additional protection for L5—S1—strapping to shorten hip extensors.



**Fig. 19.** Normal neonatal knee flexion contracture.



**Fig. 20.** Pathologic capsular knee flexion contracture with short anterior cruciate ligament.

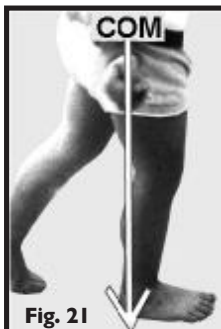

Fig. 21

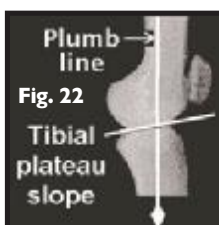


Fig. 22

**Fig. 21.** Age three years. Normal, functional, load-bearing knee angle.

**Fig. 22.** Mature knee, normal slope. The maximum contact surface area is retroverted ~5° to 10°.<sup>21</sup>

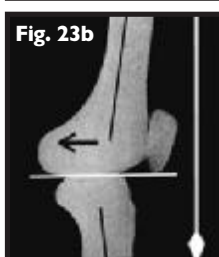

Fig. 23a

**Fig. 23a.** Age four. Right hemiplegia. Excessive knee hyperextension.

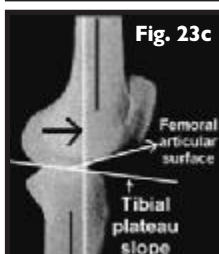


Fig. 23b

**Fig. 23b.** Standing X-ray of a mature knee joint, hyperextended. Note the modeling effect on the tibial plateau slope.<sup>21</sup>

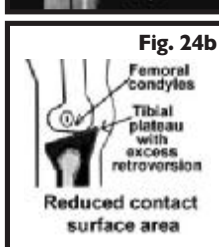


Fig. 23c

**Fig. 23c.** Same knee in corrected alignment. Note anteverted tibial slope, markedly reduced contact surface area.

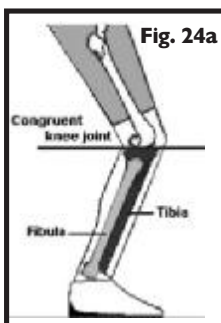


Fig. 24a

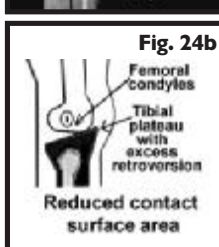


Fig. 24b

(*Pediatric Orthopedics Part IIIa continued from page 12*)

## CLINICAL IMPLICATIONS—RECTUS FEMORIS DOMINANCE

A dominant RF is evident when the 2-joint test reveals an extended knee (Fig. 16). As was discussed in Part 2 of this series, by the mechanism of relative flexibility, a dominant/shortened RF increases the anterior pelvic tilt and promotes patella alta (Fig. 17).

To protect the lumbosacral joint from hypermobility strains, TheraTogs strapping can be used to shorten and assist the lower abdominals and hip extensors (Figs 18a and 18b), in combination with strengthening of those muscles, gently and carefully elongating the RF with the pelvis stabilized, and a postural training program.

## THE FEMUR

Most notable changes in femoral geometry occur in frontal and transverse planes. The neonatal femoral shaft is bowed anteriorly,<sup>21</sup> though it appears to be laterally bowed due to the coexisting hip flexion and lateral rotation contracture. Resolution of bowing occurs by “flexure drift” following a history of loading—i.e. cantilever flexure. The timing is not known, though the “watershed” age for resolving most immature LE skeletal alignment features is ~age eight years.<sup>22</sup>

## THE KNEE JOINT

### Flexion Contracture

The normal neonatal knee flexion constraint = ~20°, regardless of the adjacent hip position, due to a shortened posterior capsule and anterior cruciate ligament (Fig. 19). Knee extension ROM increases at an average rate of 3.5°/month during the first three months, after which the rate slows to 2.8°/month until age six months, when the mean knee extension ROM deficit is negligible at 3.3°. By age 12 months, full knee extension ROM is expected.<sup>23</sup> Knee extension ROM increases to ~10° past 0° through early childhood.<sup>24</sup> By age 8 years, ideal knee extension ROM = 0°, +/- 5°.

## CLINICAL IMPLICATIONS OF KNEE EXTENSION ROM DEFICIT

The normal changes in knee extension ROM, from intrauterine limitation to hyperextension in early childhood, can be expected to participate in skeletal modeling of the knee joint (discussed below), and in the development of coordinated control of the hip and knee musculature. Persistent knee flexion would impose excessive internal moment on the anterior thigh muscles as they resist further flexion, and on the hip extensors and proximal hamstrings, as they work to prevent collapse into hip flexion. The period of hyperextension in early childhood allows the knee-controlling musculature to rest in standing position, as the knee joint falls posterior to the load line of the COM.

Knee flexion contracture is evident when the child is positioned in prone with the anterior thighs on the table and the legs allowed to dangle off the end of the table (Fig. 20).

### Tibial Plateau Slope

Warwick et al (1973), cited by Bernhardt (1988), evidently stand alone in describing the proximal tibial plateau as retro- (continued on page 14)

(Pediatric Orthopedics Part IIIa continued from page 13)

verted (oriented posteriorly) an average of  $27^\circ$  in the newborn,  $17^\circ$  at age three years,  $7^\circ$  at age 10 years, and  $5^\circ$  at age 19 years.<sup>25</sup> Bernhardt<sup>26</sup> suggests that the immature increased plateau retroversion facilitates mechanical knee extension in weight-bearing positions—like a ramp that is tilted posteriorly—while the child develops adequate muscle control of knee joint alignment.

Modeling mechanisms for resolving the normally excessive tibial plateau retroversion might involve either the resulting application of growth-enhancing compression loads between the anterior distal femoral condyles and the posterior aspect of the tibial plateau, or a resulting application of excessive compression on the anterior aspect of the proximal tibial epiphysis—diminishing the growth rate and allowing the posterior aspect of the proximal tibia to grow (via Heuter-Volkman law). In the early years following infancy, normal knee hyperextension in standing might also contribute to the flattening of the tibial plateau and inferior femoral condyles, as well as to the formation of the mature plateau slope. Normative data on the age related maturation of the tibial slope is needed.

#### CLINICAL IMPLICATIONS OF MODELING EFFECTS ON THE TIBIAL PLATEAU SLOPE

Skeletal X-rays rarely address the status of the tibial slope as a possible influence on pediatric knee joint alignment and stability. Yet, hamstring lengthenings are a common intervention for children with knee-flexed stance and gait, and pathomechanical knee hyperextension often follows the surgery. If a history of knee hyperextension in standing only (the case in Fig. 23a) can result in an abnormally anteverted tibial slope (Fig 23b), then it follows that a history of flexed-knee stance and gait

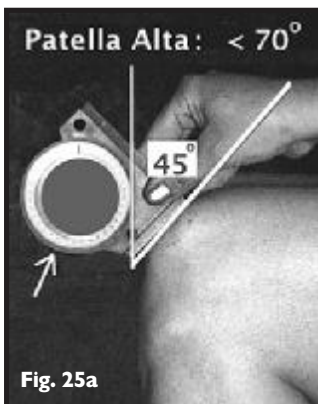


Fig. 25a

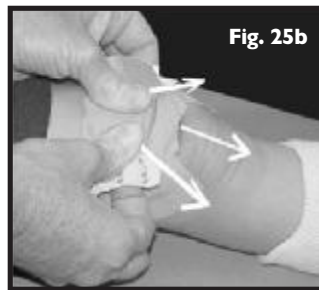


Fig. 25b

**Fig. 25a.** Patella angle indicates patella alta. **Fig. 25b.** On clean skin, knee flexed  $\sim 20^\circ$ , an underlayer of KinesioTape or OmniFix tape is applied

without tension around the superior and lateral knee joint, including the upper patella. Then, several pieces of tape are used to replace the thumbs that press the patella downward, shortening the patella tendon. If skin wrinkles under the tape, change it every 2 days.

(Fig. 24a) would result in excessive tibial slope retroversion (Fig 24b).

In this situation, a posterior soft tissue release that permits full knee extension would bring the tibial shaft to vertical and cause the femur to slide backward down the extra-retroverted tibial plateau. The child might

retain the ensuing knee hyperextension. Or, (s)he might return to using the more mechanically stable flexed-knee alignment, where the forward-tilted tibia aligns the load-bearing plateau more horizontally, restoring the increased joint contact surface area and the more competent load-bearing function.

#### The Patellofemoral Joint

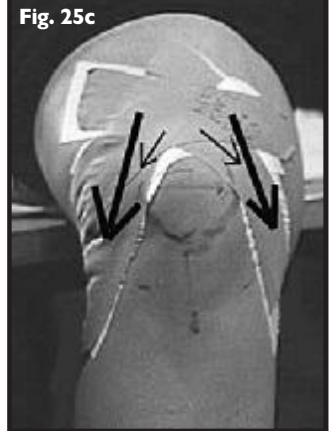The patella is designed to operate like a pulley to afford considerable leverage ( $M = F \times D$ ) to reduce the quadriceps deceleration workload during the  $10^\circ$  to  $20^\circ$  of knee flexion that occurs in early stance phase of gait, 5,000 to 10,000 steps/day.

Preliminary normative findings on nondisabled, asymptomatic children and adults—all positioned in sitting with hips and knees flexed  $90^\circ$ —suggest that the anterior surface of the patella aligns in near-vertical position ( $70^\circ$  to  $90^\circ$ ) when measured with a gravity-driven level. In the same test position, the superior border of the patella is located lower than—or or more distal to—the peak of the lateral femoral trochlear.<sup>27,28</sup>

#### CLINICAL IMPLICATIONS – THE SAGITTAL PLANE PATELLOFEMORAL JOINT

Proximal migration of the patella into the femoral trochlear groove (patella alta) increases patello-femoral contact pressure and friction, and reduces the mechanical advantage for the quadriceps by drawing the pulley off the knee joint axis. Patella alta is usually developmental and occurs in children with various problems of neuromuscular control and an inappropriate use of the RF—a swing-phase muscle—to help to sustain load-bearing knee extension. In a study of 117 ambulatory children with CP, mean age 13 years, 7 months, 193 knees were examined, and 179 showed patella alta.<sup>29</sup>

Patella alta is frankly evident when the patella (continued on page 15)



**Fig. 25c.** Orthopedic taping for patella alta with lateral deviation; OmniFix underwrap and Leukotape-P.

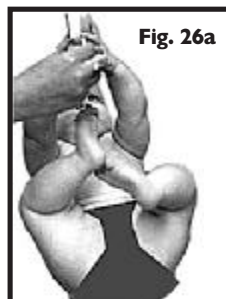


Fig. 26a

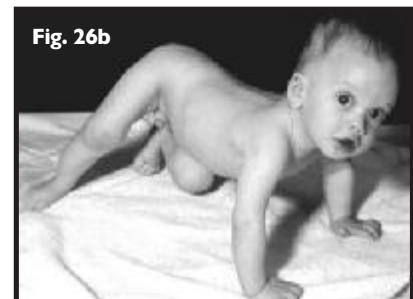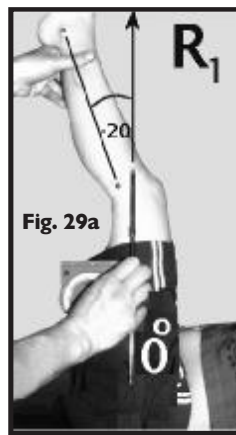

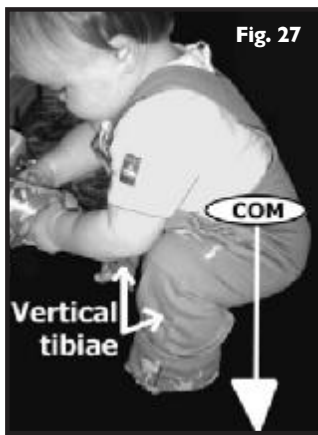


Fig. 26b

**Fig. 26a.** Age 4 months. Postural symmetry and antigravity flexion. **Fig. 26b.** Age 10 months. Bear standing activates torso and shoulder flexors, elongates HS.



(Pediatric Orthopedics Part IIIa continued from page 14)



**Fig. 27.** Age 12 months. Normal squatting position with vertical tibias.

**Fig. 28.** Age 28 months. Normal hyperex-tended HLT with no  $R_1$ .

**Fig. 29a.** Age 4 years. Normal HLT  $R_1$  end range.

**Fig. 29b.** Age 4 years. Normal  $R_2$  HLT end range.

angle in sitting diminishes to  $45^\circ$  or less, and when the proximal border of the patella is raised to a level that is even with or higher off the examining table than the anterior distal femoral trochlear.<sup>33</sup> I consider a patella angle  $\leq 70^\circ$  to be pathomechanical (Fig. 25a), and intervene to protect the patello-femoral joint from degenerating by readily using patella alta taping in conjunction with closed-chain strengthening of the hip extensors, quadriceps, and calf musculature (Fig. 25a and Fig. 25b). Note: Tape removal must be slow and gentle, following a soaking with vegetable oil (spray on type works well). I do not use skin prep under tape at the patella, as the tape tends to fall off early.

### HAMSTRING MUSCLE LENGTH

The distal portion of the hamstring muscles and surrounding soft tissues are shortened at birth, and exhibit a linear increase in length throughout the first two years of life, despite a growing repertoire of complex movement skills. Four key factors seem to influence this steady gain in hamstring muscle extensibility:

1. Antigravity flexion skill and strength brings shortened hamstring muscles into lengthened positions between ages 4 and 10 months (Figs. 26a and 26b).
2. Competent trunk control liberates the limb musculature for recruitment for movement rather than postural stability.
3. Cruising provides practice in shifting body weight over the feet while maintaining upright equilibrium.
4. Around age 12 months, Weck has observed that early walking, and hundreds—if not thousands—of transitions between squatting with knees wide apart and standing (Fig. 27), feature a remarkable maintenance of vertical or near-vertical tibias, with limited ankle dorsiflexion (DF) past  $0^\circ$ . The infant undertakes vertical weight shifts posterior to these upright tibias, loading heels heavily, activating ankle DFs, and engaging and strengthening the quadriceps and gluteals. Hamstring muscles need not be recruited with the COM so posteriorly displaced.

### CLINICAL ASSESSMENT

The hamstring length test (HLT) is often inaccurately named “popliteal angle” (PA). The original “popliteal angle” test assessed hamstring muscle extensibility in battery of tests designed to determine the gestational age of premature infants. Lying supine, the test limb is brought into maximum hip flexion, such that the anterior thigh contacts the anterior torso. The knee joint is then passively extended, and the finding is measured as the posterior aspect of the resulting knee joint angle. A finding of  $180^\circ$  would indicate the presence of full, passive knee extension.<sup>30</sup>

Kato et al (2004) observed that the popliteal angle in infants born at body weight  $<2000$ grams is significantly lower (more flexed) when these infants reach corrected age four months.<sup>31</sup> The authors advise that serial assessment of the popliteal angle is necessary before judging that a low birth weight infant has spastic cerebral palsy.

In the HLT, the test-side hip is flexed  $90^\circ$ , the sacrum is on the table, and the opposite hip is comfortably, not forcibly, extended. The findings are obtained as the angle that the fibula subtends with a vertical extension of the femur. Full knee extension is recorded as  $0^\circ$ .<sup>32</sup> Ideal  $R_1$  end ranges are presented in Fig. 28 and Fig. 29a, with a corresponding  $R_2$  end range shown in Fig. 29b.

Reade et al (1984) normed the HLT (misnamed PA) in a study of 130 infants of ages  $\geq 12$  months. After encountering an initial resistance to knee extension, they slowly pressed on to record the  $R_2$  end range. They reported a steady gain in HS extensibility, with an average finding of  $-27^\circ$  (flexed  $27^\circ$ ) in the newborns, and  $0^\circ$  by age 12 months.<sup>33</sup>

Katz et al (1992) collected HLT (misnamed PA) data from 482 nondisabled children, ages one to 10 years.<sup>34</sup> They acquired a single finding for each subject, rather than the “functional” ( $R_1$ ) and “organic” ( $R_2$ ) findings that their primary source, Reimers<sup>35</sup>, described. Clarity and replicability problems notwithstanding, Katz et al discovered a developmental trend that features a significant reduction of HS extensibility at age four years, with a mean knee extension deficit averaging  $26^\circ$  (by their method) through age 10 years. (The HLT technique is fully demonstrated on the DVD, *Legs & Feet: A Review of Lower Extremity Muscu-* (continued on page 16)

(Pediatric Orthopedics Part IIIa continued from page 15)

*loskeletal Assessments*, 3rd edition, 2005, available at [www.gaitways.com](http://www.gaitways.com).) Katz et al's normal means align rather closely with the  $R_1$  end ranges of  $-25^\circ$  to  $-30^\circ$  that I commonly see in nondisabled children.

Most children of ages one through two years exhibit little or no notable distinction between  $R_1$  and  $R_2$  end ranges at any muscle group, and so the HLT measurement for children in this age group is typically a single observation ( $R_1 = R_2$ ) (Fig. 28). A distinct  $R_1$  end range emerges between ages three and four years.

Discrepancies in reported neonatal and pre-adolescent HS length status suggest that variances lie with a lack of standardization of testing methods, including the stabilization of proximal or distal segments, the recording of both  $R_1$  or  $R_2$  end ranges, and the speed of execution of the test, and variances in the time of day of testing.

## CLINICAL IMPLICATIONS OF NORMATIVE HS LENGTH DATA

*Shortened HS have been implicated as a contributing factor in hip subluxation, low back pain, flat back posture, pelvic motion limitation, increased thoracic kyphosis in sitting, patella alta, shortened step length, certain athletic performance difficulties, and an increased incidence of sports-related HS injuries.<sup>36</sup> For these reasons, I use the means as a clinical guide in goal setting, and the findings that fall within the second standard deviation around the means as biomechanically irrelevant data.*

*Any notable resistance to knee extension in children between ages 12 and 36 months suggests that the HS are excessively active. Find and address the source of compensatory HS recruitment.*

*Children ages  $<9$  to 12 months and  $>3$  years do not typically exhibit full ( $0^\circ$ ) passive knee extension at  $R_2$  end range in a HLT.  $R_1 = -30^\circ$  is a reasonable management goal for children  $\geq$  age 4 years, and an ideal finding for adolescents and adults, with  $10^\circ$  to  $20^\circ$  of unforced extensibility past  $R_1$  end range.*

*Trunk extensor muscle weakness often precipitates compensatory, excessive recruitment of HS for sitting stability in infants and young children with CNS dysfunction, promoting their typical dominance and shortening. This relationship becomes evident upon providing adequate manual trunk stabilization, whereby the HS relax.*

*The anterior displacement of the COM in gait requires that the HS, along with other dorsal muscles, be recruited excessively in order to remain upright.*

*Shortened (dominant) HS are evidence of chronic, excessive recruitment. HS extensibility can be expected to improve with gains in trunk control and in weight line distribution onto the heels in standing and walking.*

## The Tibia

*Tibial bowing.* Bowing of the neonatal tibial shaft is unclear, as Badelon et al<sup>37</sup> and Grant et al<sup>38</sup> report and show no evidence of tibial bowing in any plane, while Warwick et al (1973) suggest that they have identified various posteriorly directed bends.

## The Talocrural (Ankle) Joint

The osseous features of the developing ankle and foot entail an elaborate, triplanar discussion that requires preliminary knowledge of accurate nomenclature. This section addresses those sagittal-plane features that are clinically visible and relevant to this discussion.

A normal bias of ankle DFROM over PFROM shows that the normal fetal ankle is dorsiflexed during the final weeks of gestation.<sup>31</sup> DFROM at birth averages  $\sim 60^\circ$  (Fig. 30).<sup>39</sup> Plantarflexion is constrained by shortened tissues on the ankle dorsum. As age 12 months approaches, passive DFROM diminishes.

Wong et al (1998) measured passive ankle DFROM in 26 nondisabled infants, ages seven to 14 months, lying supine with the test knee extended. They found a mean DF of  $45^\circ$  among the "prewalkers", who could stand assisted when placed; and  $38^\circ$  DF among the "new walkers".<sup>40</sup>

Sutherland et al (1988) also measured passive DFROM with the children positioned in supine with knee extended. They obtained a median finding of  $25^\circ$  DFROM at age one year—considerably lower than the norms reported by others<sup>40,41</sup>—and a median of  $15^\circ$  DF at ages four through seven years, also considerably lower than my findings.<sup>24</sup> Perhaps the examiners supinated the foot during these tests.

Tardieu et al (1987) suggest that a child of age four years can be expected to exhibit an  $R_1$  (noted as  $A_0$ ) ankle DFROM of  $-5^\circ$ , and  $R_2$  end range (noted as  $A_{\max}$ ) of  $26^\circ$ .<sup>42</sup> No body of data supports this statement. I generally find  $R_1$  end range between  $+5^\circ$  and  $+10^\circ$  in nondisabled children of age four years. The Tardieus use a mechanical device to apply DF loads and that calibrates resistive tension at five-degree increments, and I do it manually, which probably accounts for the difference in our impressions of  $R_1$  end range. In my experience, healthy adults, lying prone with the knee extended and the foot joints aligned in full congruity, commonly exhibit passive  $R_1/R_2$  DF ranges of about  $0^\circ/10^\circ$  respectively. Significantly greater findings are obtained when the foot is allowed to pronate during this procedure.

At the heel-rise phase of propulsion in gait, mature triceps surae contract at an ankle joint angle approaching  $0^\circ$ , and generate  $\sim 45\%$  of the acceleration energy needed for forward walking.<sup>43,44</sup> This calf muscle contraction can generate so much force only when the contractile force is multiplied by the length of the stable (i.e. congruent or supinating) foot, measured from the posterior calcaneus to first metatarsophalangeal joint. Adults typically take between 5,000 and 10,000 steps daily. Children take more steps than adults, and spend more than 10 years developing the full deceleration and propulsion function of the calf musculature and the foot.<sup>45,46</sup>

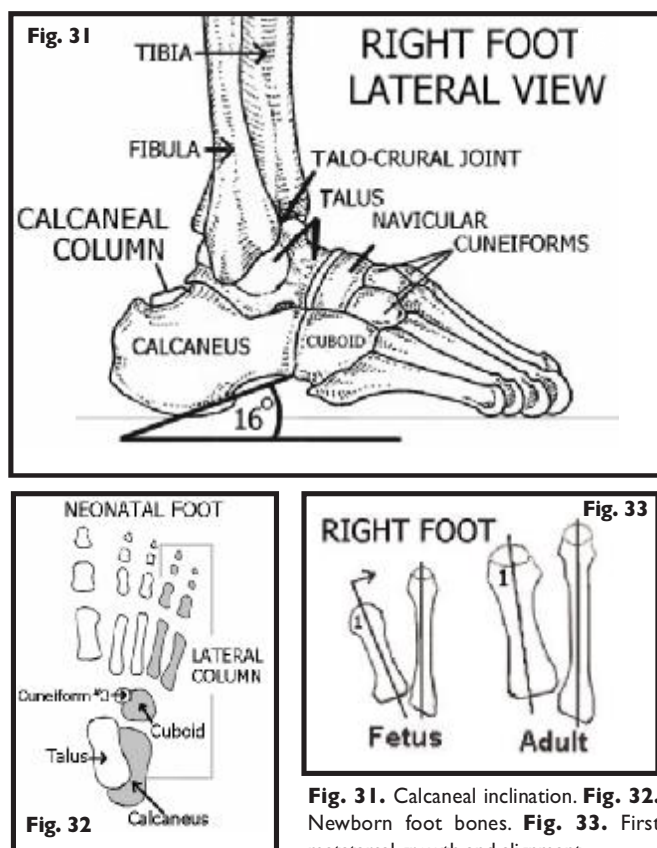
From Part II of this series, recalling that  $R_1$  end range is the position of optimum isometric contractile strength in a muscle's arc of extensibility, I surmise that the normal history of thousands of daily contractions at propulsion sets the  $R_1$  end range, with many years of walking passing before the resting muscle length for the calf musculature is established. Like hamstring muscle length,  $R_1$  ankle DFROM appears to be developmental, emerging by age  $\sim 4$  years in



**Fig. 30.** Normal neonatal DF ROM.



(Pediatric Orthopedics Part IIIa continued from page 16)



**Fig. 31.** Calcaneal inclination. **Fig. 32.** Newborn foot bones. **Fig. 33.** First metatarsal growth and alignment

non-Asian children, and set by a history of use that is accompanied by a decrease in connective tissue length and an increase in stiffness.

### ANKLE DFROM ASSESSMENT

The method of assessing passive ankle DFROM is among the most variable of the musculoskeletal assessments and rarely features the  $R_1$  end range finding.<sup>47</sup> Consider the significance of reported norms in the context of the assessment technique that was used to acquire them.<sup>50</sup>

### CLINICAL IMPLICATIONS— PEDIATRIC TALOCRURAL ROM

*Normal  $R_2$  (maximum) ankle DFROM is never 0°. Any resistance to passive DF in a child less than age three years is pathological. Knowledge of pediatric norms and trends for soft-tissue extensibility can guide the clinician to design and intervene to support appropriate management goals for children with calf muscle hypoextensibility. I use heel wedges to accommodate the DF ROM deficit in standing—bringing the ground up to the heel—and training the child to loading his or her body weight on them in standing and, when ready, in gait.*

### THE FOOT

The foot grows at a rate approaching that of the body as a whole,

but asynchronously when compared with growth of the long bones of the lower extremity. The foot grows rapidly in length at a decreasing rate, during the first five postnatal years. Adult length is gained first at the foot, then in the lower extremities, and finally in stature.<sup>48</sup> By age 12 months in girls and 18 months in boys, the foot can be expected to have achieved half its potential adult length when measured from the posterior heel to the tip of the hallux. From age five to 12 years (girls) or five to 14 years (boys), the average annual rate of foot growth is .9cm. Boys and girls exhibit comparable foot sizes through age 12 years. After age 12, foot growth slows to .4cm per year for another two years in girls. Foot growth continues for boys until age 16 years, with an average foot length of 2.2cm longer than that of girls of comparable age.<sup>49</sup>

The calcaneal column protrudes posteriorly beyond the calcaneal body and the weight-bearing facet, connecting the calcaneal body to the calcaneal apophysis. As it has with human evolution, calcaneal column length increases with age.<sup>50</sup> Ample column length enhances the mechanical advantage for the triceps surae muscle group, conserving energy as the soleus muscle decelerates the progressing tibia in midstance, and while the gastrocnemius and soleus propel the body forward at heel-rise.<sup>51,52</sup> The calcaneal apophysis begins to ossify at age 4 to 6 years in girls, fusing with the calcaneal body at ~age 16 years. In boys, the apophysis begins ossifying between ages five and 9 years, fusing to the calcaneal body at about 20 years of age.<sup>48</sup>

The angle of load-bearing calcaneal DF, known as the *calcaneal inclination*, is formed by the intersection of the plantar calcaneal border and the floor (Fig. 30). The entire calcaneal column and body are dorsiflexed off the floor in weight-bearing conditions throughout life. The DF angle increases from 9° to 12° in early infancy to 15° to 30° in adolescence.<sup>53</sup> The calcaneal inclination sets the calcaneocuboid joint in a suspended position to form a truss-like vault.

The calcaneus, cuboid, and the lateral two metatarsals form the lateral column of the foot, where most load bearing occurs (Fig. 31). The shift in load distribution from medial to lateral columns of the foot has been observed in infants and children between ages 18 and 48 months.<sup>54</sup>

The neonatal first metatarsal is considerably shorter and more adducted than the second metatarsal (Fig. 32). Growth in length and adduction reduction are modeling effects of early foot pronation, with excessive loading of the medial forefoot, normal heel rises while cruising, toe-walking, and gains in ligament integrity and muscle strength in the foot.

With heel rise at early propulsion in gait, the first and second metatarsal heads operate like the wheel on a wheelbarrow. The first ray plantarflexes while the flexor hallucis joins the triceps surae in generating propulsion force. The resulting longitudinal compression through the first metatarsal shaft continues to promote growth in length and diameter. The first and second metatarsals are ideally nearly equal in length, the second being a few millimeters longer than the first to accommodate the transfer of weight to the opposite foot. Most design features of the foot bones are accomplished by age eight years. (continued on page 18)

(Pediatric Orthopedics Part IIIa continued from page 17)

Mature gait features two peaks in vertical loading (and ground reaction force) during the stance phase—the first at weight assumption and the second at propulsion—indicating that compression force is greater in magnitude than body weight.<sup>55</sup> The same loading pattern slowly emerges in children, appearing in immature form at age three years, and gaining definition at age five years.<sup>56,57</sup> Between ages 18 and 48 months, the peak loading pressures increase, particularly at the heel.<sup>54</sup> After age five years, magnitudes of ankle power increase and of hip and knee power decrease in the gait cycle. These force patterns reflect the developing power of the calf musculature, including the Flexor Hallucis Longus, and the foot's evolving stability and propulsive capacity in the context of the sagittal-plane function of walking.

### CLINICAL IMPLICATIONS OF SAGITTAL-PLANE FOOT CONFIGURATION

Any measure, such as an Achilles tendon lengthening, that is intended to deliberately reduce potential ankle plantarflexion power in a child is an aggressive intervention in light of the potential cost to gait efficiency as the child grows taller and heavier. The failure of all attempts to train the child to distribute her COM over the heels, and in that context, repeated failure of conservative measures to reduce gait pathomechanics related to inadequate tibial progression, including prolonged, low-load, daily stretching, repeated serial casting courses, and/or adding heel wedges to shoes, might warrant a cautious surgical intervention when growth is nearly complete.

The calcaneal inclination leads the way to designing plantar contours for orthotic inserts for young children. For the foot that lacks spring-like resilience in the ligaments, aponeurosis, or through dynamic muscle function, the clinician might seek to support the calcaneocuboid joint with adequate plantar contouring—along the lines of well-known German sandals—featuring a recessed heel seat and a lateral, as well as medial, longitudinal arch. Triplanar calcaneal and midtarsal joint stabilization can be improved

by using an appropriately contoured arch support to sustain the calcaneal inclination and the more distal calcaneocuboid joint in the sagittal plane.<sup>58</sup>

### SUMMARY

Infants and young children achieve the two primary ingredients of antigravity movement—extension and flexion—and build postural control and movement off of them. In terms of sagittal-plane movement pathology and contracture formation, I suggest that a fundamental management goal for all children is to see that reliable trunk and hip extension against gravity is achieved. For children who are upright, I aim to accomplish confident and useful weight-loading through the heels.

In Part IIIB, later this year, we will review a comparable collection of developmental features occurring primarily in the frontal plane.

Beverly Cusick, PT, MS, COF/BOC, is president of Progressive GaitWays, LLC, in Telluride, Colorado. She can be reached at [billi@gaitways.com](mailto:billi@gaitways.com), or at [bcusick@theratogs.com](mailto:bcusick@theratogs.com)

### REFERENCES:

1. Bly L. *Motor Skills Acquisition in the First Year: An Illustrated Guide to Normal Development*. San Antonio, TX: Psychological Corporation/Therapy Skill Builders; 1994.
2. Jensen JL, Thelen E, Ulrich BD. Constraints on multijoint movements: from the spontaneity of infancy to the skill of adults. *Hum Movement Sci* 1989; 8: 393-402.
3. Green EM, Mulcahy CM, Pountney TE. An investigation into the development of early postural control. *Dev Med Child Neurol* 1995; 37: 437-448.
4. Bagnall KM, Harris PF, Jones PR. A radiographic study of the human fetal spine, 1: the development of the secondary cervical curvature. *J Anat* 1977; 123: 777-782.
5. Hensinger R, Jones E. Developmental orthopedics, 1: the lower limb. *Dev Med Child Neurol* 1982; 24: 95-116.

6. Asher C. Postural patterns from birth to maturity. In: *Postural Variations in Childhood*. Boston, Mass: Butterworths; 1975.
7. Winter RB. Scoliosis and spinal growth. *Orthop Rev* 1977; 6: 17-20.
8. Gajdosik R, Simpson R, Smith R, DonTigny RL. Pelvic tilt: Intratester reliability of measuring the standing position and range of motion. *Phys Ther* 1985; 65(2): 169-172.
9. Heino JG, Godges JJ, Carter CL. Relationship between hip extension range of motion and postural alignment. *J Orthop Sports Phys Ther* 1990; 12: 243-247.
10. Gajdosik R, Simpson R, Smith R, DonTigny RL. Pelvic tilt: intratester reliability of measuring the standing position range of motion. *Phys Ther* 1985; 65: 169-174.
11. Norkin CC, White DJ. *Measurement of Joint Motion. A Guide to Goniometry*. Edition 2. Philadelphia, Pa: FA Davis Company; 1995.
12. Boyd RN, Ada L. Physiotherapy management of spasticity. In: Barnes M, Johnson G, (Eds) *Upper motor neurone syndrome and spasticity: Clinical management and neurophysiology*, 96-121. Cambridge, England: Cambridge University Press; 2002.
13. Kilgour G, McNair P, Stott NS. Intratester reliability of lower limb sagittal range-of-motion measures in children with spastic diplegia. *Dev Med Child Neurol* 2003; 45(6): 391-399.
14. Forero N, Okamura LA, Larson MA. Normal ranges of hip motion in neonates. *J Pediatr Orthop* 1989; 9: 391-395.
15. Coon V, Donate G, Houser C, Bleck EE. Normal ranges of hip motion in infants six weeks, three months, and six months of age. *Clin Orthop* 1975; 110: 256-258.
16. Staheli LT. The prone hip extension test. *Clin Orthop* 1977; 123: 12-15.
17. Phelps E, Smith LJ, Hallum A. Normal ranges of hip motion of infants between nine and 24 months of age. *Dev Med Child Neurol* 1985; 27: 785-792.

(continued on page 19)

(Pediatric Orthopedics Part IIIa continued from page 18)

18. Gilliam J, Barstow IK. Joint range of motion. In Van Deusen J, Brunt D. (Eds): *Assessment In Occupational Therapy And Physical Therapy*, 49-77. Philadelphia, PA: WB Saunders Company; 1997.
19. Kendall FP, McCreary EK, Provance PG. *Muscles: Testing and Function, with Posture and Pain*, 3<sup>rd</sup> edition. Baltimore, MD: Williams and Wilkins; 1993.
20. Sahrman SA. *Diagnosis and Treatment of Movement Impairment Syndromes*. St. Louis, MO: Mosby; 2002.
21. Hensinger R, Jones E. Developmental orthopedics, 1: the lower limb. *Dev Med Child Neurol* 1982; 24: 95-116
22. Bleck EE. Developmental orthopedics, 3: toddlers. *Dev Med Child Neurol* 1982; 24: 533-555.
23. Broughton NS, Wright J, Menelaus MB. Range of knee motion in normal neonates. *J Pediatr Orthop* 1993; 13: 263-264.
24. Sutherland DH, Olshen RA, Bidena EN, Wyatt MP. Anthropometric measurements and developmental screening. In: *The Development of Mature Walking*, 33-54. New York, NY: Cambridge University Press; 1988.
25. Warwick R, Williams PL, eds. *Gray's Anatomy*. 35th ed. Philadelphia, Pa: WB Saunders Co; 1973.
26. Bernhardt DB. Prenatal and postnatal growth and development of the foot and ankle. *Phys Ther* 1988; 68: 1831-1839.
27. Hughston JC, Walsh WM, Puddu G. *Patellar Subluxation and Dislocation*. Philadelphia, Pa: WB Saunders Co; 1984.
28. Carson WG Jr, James SL, Larson L, et al. Patellofemoral disorders: physical and radiographic evaluation, I: physical examination. *Clin Orthop* 1984; 185: 178-186.
29. Topoleski TA, Kurtz CA, Grogan DP. Radiographic abnormalities and clinical symptoms associated with patella alta in ambulatory children with cerebral palsy. *J Pediatr Orthop* 2000; 20: 636-639.
30. Amiel-Tison C, Barrier G, Schnider SM, et al. The neonatal neurologic and adaptive capacity score. *Anesthesiology* 1982; 56: 492-493.
31. Kato T, Okumura A, Hayakawa F, et al. Popliteal angle of low birth weight infants during the first year of life. *Pediatr Neurol* 2004 30(4): 244-246.
32. Holt S, Baagoe S, Lillelund F, Magnusson SP. Passive resistance of hamstring muscles in children with severe multiple disabilities? *Dev Med Child Neurol* 2000; 42(8): 541-544.

(continued on page 20)

## Balance & Movement



Airex Balance Beam



Activa Balance Board

**Innovative Products  
To Improve Your  
Treatment Sessions**

**equipment shop**

Call for our free catalog & be sure to check the sale page on our website too!

P.O. Box 33 • Bedford, MA 01730 • (781) 275-7681 • 1-800-525-7681 • Fax (781) 275-4094  
E-mail: [info@equipmentshop.com](mailto:info@equipmentshop.com) • Website: [www.equipmentshop.com](http://www.equipmentshop.com)



Activa Discs



(Pediatric Orthopedics Part IIIa continued from page 19)

33. Reade E, Horn L, Hallum A, Lopopolo R. Changes in popliteal angle measurement in infants up to 1 year of age. *Dev Med Child Neurol* 1984; 26: 774-780.
34. Katz K, Rosenthal A, Yosipovitch Z. Normal ranges of popliteal angles in children. *J Pediatr Orthop* 1992; 12: 229-231.
35. Reimers J. Contracture of the hamstrings in spastic cerebral palsy: a study of three methods of operative correction. *J Bone Joint Surg [Br]* 1974; 56: 102-109.
36. Moore KL. *Clinically-Oriented Anatomy*. 3rd ed. Philadelphia, Pa: WB Saunders Co; 1992.
37. Badelon O, Bensahel H, Folinai D, Lassale B. Tibiofibular torsion from the fetal period until birth. *J Pediatr Orthop* 1989; 9: 169-173.
38. Grant JCB. *An Atlas of Anatomy*. 5th ed. Baltimore, MD: Williams & Wilkins; 1962.
39. Waugh KG, Minkel JL, Parker R, Coon VA. Measurement of selected hip, knee, and ankle joint motions in newborns. *Phys Ther* 1983; 63: 1616-1621.
40. Wong S, Ada L, Butler J. Differences in ankle range of motion between pre-walking and walking infants. *Aust J Physiother* 1998; 44: 57-60.
41. Giannestras NJ. *Foot Disorders: Medical and Surgical Management*. 2nd ed. Philadelphia, Pa: Lea & Febiger; 1973.
42. Tardieu G, Tardieu C. Mechanical evaluation and conservative correction of limb joint contractures. *Clin Orthop* 1987 219: 63-70.
43. Winter DA, Ishac M, Eng JJ, Prince R. The foot as an energy absorber and generator during stance phase of walking. *Gait Posture* 1995; 3(2): 80.
44. Winter DA, Eng P. Kinetics: our window into the goals and strategies of the central nervous system. *Behav Brain Res* 1995; 67(2): 111-120.
45. Katoh MT, Mochizuki T, Moriyama A. Changes of sagittal plane ankle motion and ground reaction force (fore-aft-shear) in normal children aged four to 10 years. *Dev Med Child Neurol*. 1993; 35: 417-423.
46. Oeffinger DJ, Augsburger S, Cupp T. Pediatric kinetics: Age-related changes in able-bodied populations. *Gait Posture* 1997; 5(2): 155-156.
47. Klevin D, Boernhoft D, Thorp B. Assessing ankle dorsiflexion. *Clin Management* 1989; 9: 25-26.
48. Saraffian SK. *Anatomy of the Foot and Ankle: Descriptive, Topographic, Functional*. Philadelphia, Pa: JB Lippincott Company; 1983.
49. Blais MM, Green WT, Anderson M. Length of the growing foot. *J Bone joint Surg [Am]*. 1956; 38: 998-999.
50. Strauss WL. Growth of the human foot and its evolutionary significance. *Contrib Embryol*. 1927; 101: 100-134.
51. Inman VT. Human locomotion. *Canadian Med Assoc J* 1966; 94: 1047-1052.
52. Saltzman CL, Nawoczenski DA. Complexities of foot architecture as a base of support. *J Orthop Sports Phys Ther* 1995; 21: 354-360.
53. Staheli LT, Chew DE, Corbett M. The longitudinal arch: a survey of eight hundred and eighty-two feet in normal children and adults. *J Bone Joint Surg [Am]* 1987; 69: 426-428.
54. Knorr P, Reichelmeier G. Development of the foot in childhood — a pedobarographic longitudinal study of children from 18 to 48 months. *Gait Posture* 1994; 2(4): 249.
55. Perry J. *Gait Analysis: Normal and Pathological Function*. Thorofare, NJ: SLACK Incorporated; 1992.
56. Preis S, Klemms A, Muller K. Gait analysis by measuring ground reaction forces in children: changes to an adaptive gait pattern between the ages of one and five years. *Dev Med Child Neurol* 1997; 39: 228-233.
57. Ounpuu S, Gage JR, Davis RB. Three-dimensional lower extremity joint kinematics in normal pediatric gait. *J Pediatr Orthop* 1991; 11: 341-349.

## Your NDT Questions are Answered Here!

### NEW DISCUSSION FORUM ONLINE WITH NDT INSTRUCTORS

- Have a question about an NDT treatment technique, but don't know where to go?
- Is your patient not responding the way you thought from what you learned in your NDT course?
- Have a complicated case and want to ask an NDT Instructor what to do first?

### NDT INSTRUCTORS WILL ANSWER YOUR QUESTIONS ONLINE ON THE Q&A WITH NDT INSTRUCTORS DISCUSSION BOARD.

Simply go to [ww.ndta.org](http://ww.ndta.org) and click on the Q & A button and post your question. A pediatric or adult hemiplegia instructor will work with you to answer your questions and to get the results that you want with your patients.

Using this Internet link, you can be connected with NDT Instructors who have gone through extensive training in the Bobaths' theory, many of them trained by Dr. Karel and Mrs. Berta Bobath, the founders of NDT. NDT instructors teach courses nationally and internationally to occupational therapists, physical therapists, and speech and language pathologists. Educational courses taught by NDT instructors include: Educational Opportunities courses, 3-day seminars, 3-week Certificate Course in the Treatment and Management of Adults with Hemiplegia, NDT/Bobath 8-week Certificate Course in the Treatment and Management of Individuals with Cerebral Palsy and NDT/Bobath Approved Advanced Courses.

**Take advantage of this unique opportunity to interact with the experts in pediatric and adult neurological rehabilitation by posting your questions online!**